



**PATIENT**

Loki Ketilson

**SPECIES**

Canine

**BREED**

Alaskan Malamute

**SEX**

Female Spayed

**AGE**

13 months

**WEIGHT**

81.6lbs

**INTERPRETED BY**

Maggie Machen Lamy,  
DVM, DACVIM  
(Cardiology)

**IMAGING PERFORMED BY**

Stephanie Cory, DVM

**HOSPITAL NAME**

Brighton Veterinary  
Clinic P. C. Inc.

**REFERRING VET**

Dr. Wagner

**INVOICE**

47586

**DATE**

4/15/26

**PRESENTING CLINICAL SIGNS**

History: History of collapse after a run on April 2nd. Went to EC; no free fluid in chest or abdomen, normal electrolytes on blood gas. They suspected of having a cardiac problem. On exam, no heart murmur, good peripheral pulses. In-house ECG normal. Echo appears normal, did find a liver mass on quick scan so proceeded to full AUS.

-Abnormal PE/Chem/CBC/UA Results: CBC/chem: Borderline anemia at 35%, stress lymphopenia, neutrophils WNL and platelets WNL. ALB 46 N: 25-44), ALP 275 (N: 20-150), ALT 179 (N: 10-118).

**ELECTROCARDIOGRAPHIC FINDINGS** \*Note: Single lead ECGs are evaluated as a rhythm strip.

Morphology/MEA cannot be definitively commented on.

A single lead ECG is available; 25mm/s, 10mm/mV. The average heart rate is 100bpm. The rhythm is sinus in origin, with a p for every QRS complex and vice versa. The P and QRS morphologies are positive. No ectopic beats, pauses or other dysrhythmias observed.

ECG diagnosis: Normal sinus rhythm with respiratory variation.

**ECHOCARDIOGRAM FINDINGS**

2D, m-mode, color flow and doppler imaging is available. Mild MV thickening with no prolapse into the left atrial lumen. No obvious mitral regurgitation with a normal left atrial dimension. Normal LV diameter with adequate myocardial function. The tricuspid valve appears normal with no tricuspid regurgitation. Normal right atrial and ventricular diameter and morphology indicating no overt evidence of pulmonary arterial hypertension. The pulmonic and aortic valves are normal in morphology and mobility. Normal pulmonic and aortic outflow velocities with laminar flow. No obvious aortic and trace pulmonic insufficiency. No pericardial or pleural effusion noted. No obvious cardiac masses.

**CARDIAC CHART**

CANINE CARDIAC PARAMETERS	MR VMAX (m/s)	TR VMAX (m/s)	LA/AO (Boon method)	LA/AO (Heart Base; Swe)	FS (%)	EF (%)	EPSS (cm)	
<b>NORMAL PARAMETER</b>	4.5-5.5	<2.7	1.3	<1.6	28-40	40-100	<0.6	
<b>PATIENT</b>	NA	NA	1.1	1.2	37	68	0.5	
CANINE CARDIAC PARAMETERS	HR (BPM)	AV VMAX (m/s)	PV MAX (m/s)	BODY WEIGHT (kg)	LA 2D short axis Base view (cm)	LVIDd Avg; 2D and m-mode short axis (cm)	LVIDs Avg; 2D and m-mode short axis (cm)	
<b>NORMAL PARAMETER</b>	50-100	0.7-1.7	0.7-1.6	BELOW	BELOW	BELOW	BELOW	
<b>PATIENT</b>	NM	1.0	0.8	37.0	3.1	3.9	2.4	
<b>*Normal chamber parameters expressed as a mean value (SD)</b>					3	1.27 (5.3)	2.46 (2.46)	1.36 (5.5)
<b>BODY WEIGHT DEPENDENT PARAMETERS</b>					5	1.40 (4.5)	2.74 (5.2)	1.60 (4.7)
<b>*Note: All measurements based upon multi-modal images and methods. An average value is reported.</b>					10	1.50 (3.8)	3.27 (3.5)	2.06 (3.1)
					15	1.83 (2.0)	3.71 (2.4)	2.43 (2.1)
					20	2.02 (1.9)	4.14 (2.2)	2.80 (2.0)
					25	2.18 (2.4)	4.48 (2.9)	3.10 (2.5)
					30	2.33 (3.3)	4.83 (3.9)	3.39 (3.4)
					35	2.48 (4.3)	5.17 (5.0)	3.69 (4.5)

Adapted from June Boon, Veterinary Echocardiography, 1998  
Rishniw M and Hollis NE, J Vet Intern Med 2000; 14:429-435



**PATIENT**

Loki Ketilson

**SPECIES**

Canine

**BREED**

Alaskan Malamute

**SEX**

Female Spayed

**AGE**

13 months

**WEIGHT**

81.6lbs

**INTERPRETED BY**

Maggie Machen Lamy,  
DVM, DACVIM  
(Cardiology)

**IMAGING PERFORMED BY**

Stephanie Cory, DVM

**HOSPITAL NAME**

Brighton Veterinary  
Clinic P. C. Inc.

**REFERRING VET**

Dr. Wagner

**INVOICE**

47586

**DATE**

4/15/26

Hansson et al, Vet Rad and Ultrasound 2002	40	2.62 (5.2)	5.48 (6.1)	3.96 (5.4)
Bonagura et al. Echocardiography: principles of interpretation, Vet	50	2.88 (7.1)	6.07 (8.3)	4.46 (7.4)

**INTERPRETATION OF THE FINDINGS & FURTHER RECOMMENDATIONS**

Overtly normal cardiac dimensions and function, with no obvious dysfunction or dilation of the left heart. No significant valvular leaks are visualized, and no evidence of pulmonary hypertension. The ECG is unremarkable with a respiratory sinus arrhythmia.

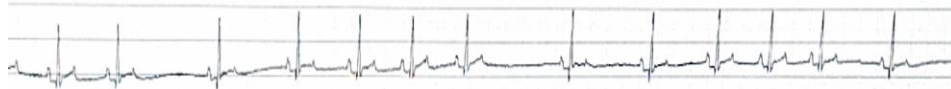
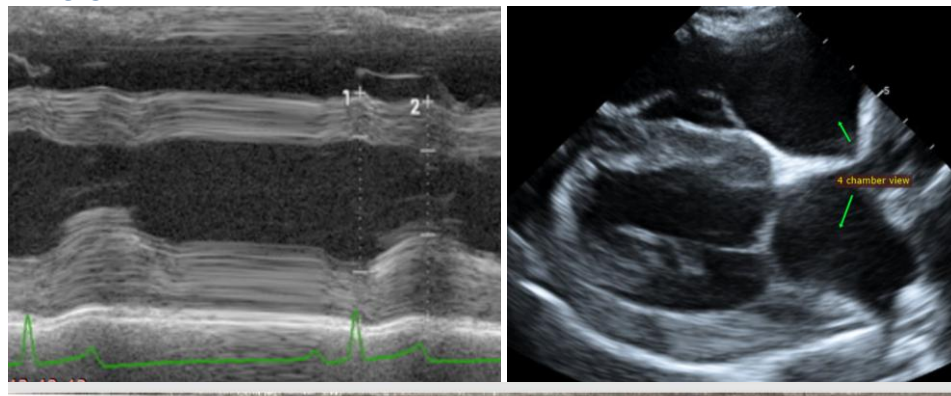
These findings would suggest a cardiac cause for the recent episode is unlikely. Further workup, including an ECG if there is still a concern for syncope. A baseline BP should also be assessed.

No medications are indicated and the prognosis is open from a cardiac standpoint.

Monitor for development of a heart murmur, cough, labored breathing, exercise intolerance or collapse episodes.

A recheck echocardiogram is recommended should a significant murmur develop or signs of cardiac compromise be noted in the future.

**IMAGES**



**The information and recommendations provided are based on the images presented by the referring veterinarian. No evaluation can be communicated regarding pathology that was not visible in the image/video clips provided.**

Thank you for this referral. This report was generated using transcription software, and minor dictation errors may be present. If the clinical or image interpretation does not parallel your findings or if I can be of any further assistance, please contact me.

**Maggie Machen Lamy, DVM**  
**Diplomate of the American College of Veterinary Internal Medicine (Cardiology)**  
 info@sonopath.com